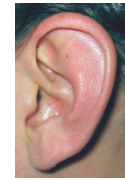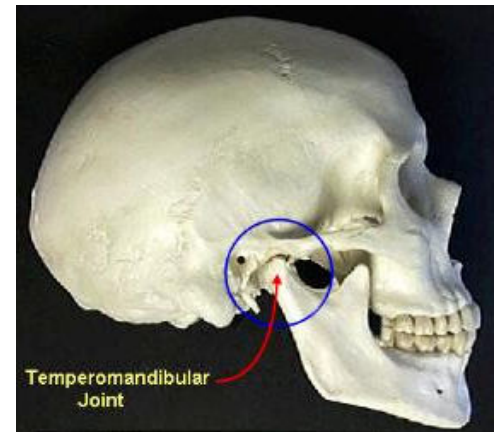
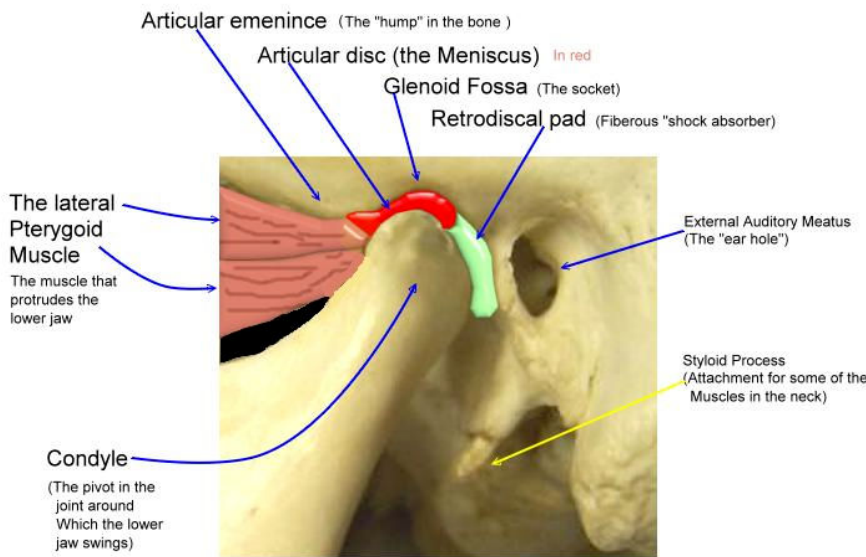




TINNITUS



- Tinnitus – "Ringing in the ears" or another noise that seems to originate in the ears or head. Tinnitus is due to diverse causes including ear infections, fluid in the ears, Meniere syndrome, medications such as aspirin and other nonsteroidal anti-inflammatory drugs (NSAIDs), aging, and ear trauma from the noise of planes, firearms, or loud music. In rare situations, tinnitus may reflect an aneurysm or an acoustic neuroma (a benign tumor on the acoustic nerve). MedicineNet.com
- .Pronunciation: \ti-nə-təs, tə-nī-təs\ Function: *noun* Etymology: Latin, ringing, tinnitus, from *tinnire* to ring, of imitative origin. Date: 1843 : a sensation of noise (as a ringing or roaring) that is caused by a bodily condition (as a disturbance of the auditory nerve or wax in the ear) and typically is of the subjective form which can only be heard by the one affected. Merriam-Webster Online



- What is missing?? In both definitions, there is NO mention of any relationship of the ear canal to the Temporal Mandibular Joint (TMJ) the hinge joint just in front of the ear!! The TMJ is part of the lower jaw that holds the lower teeth.
- When inflammation or trauma to the TMJ occurs the swelling is in front of the ear canal, not inside. The medical doctor may examine the ear canal and see NO signs of inflammation, no redness. Often the patient is told to just live with tinnitus. A dental evaluation is the next step, by a dentist that treats occlusion and TMJ health.
- The connection of tinnitus to dentistry is through the jaw bones. The bones move based on the way the teeth meet together. In a healthy bite, the muscles and the TMJ are in harmony. When the bite is not healthy, the lower jaw may be forced out of the healthy position and press back towards the ear canal. Inflammation of the retrodiscal area will press on the ear canal. A dentist is needed to evaluate the occlusion (bite). A bite discrepancy is one way that tinnitus may be activated.
- Treatment from a dentist begins with examination and diagnosis. JVA or Joint Vibrational Analysis allows for a non-invasive evaluation of the TM joint. MRI is another tool to evaluate the condition of the structures surrounding the joint. If the bite is determined to be contributory then solutions may include: Bite guard appliances, equilibration, and rehabilitation of worn teeth or old fillings to correct the failing bite. A digital evaluation of the bite is done with a Tek-Scan III. This shows the functional bite in real time and allows precise changes for the best bite.



Stephen G. Blank, D.D.S.
RESTORATIVE AND AESTHETIC DENTISTRY

184 NW Central Park Plaza

www.psldentist.com
772-878-7348

Saint Lucie West, FL 34986